
The SNMMI and EANM Practice Guideline for Small-Bowel and Colon Transit 1.0*

Alan H. Maurer¹ (Chair), Michael Camilleri², Kevin Donohoe³, Linda C. Knight¹, Jan L. Madsen⁴, Giuliano Mariani⁵, Henry P. Parkman¹, and Janice Van Dolsen¹

¹Temple University School of Medicine, Philadelphia, Pennsylvania; ²Mayo Clinic, Rochester, Minnesota; ³Beth Israel Deaconess Medical Center, Boston, Massachusetts; ⁴Hvidovre Hospital, Hvidovre, Denmark; and ⁵University of Pisa Medical School, Pisa, Italy

PREAMBLE

The Society of Nuclear Medicine and Molecular Imaging (SNMMI) is an international scientific and professional organization founded in 1954 to promote the science, technology, and practical application of nuclear medicine. Its 18,000 members are physicians, technologists, and scientists specializing in the research and practice of nuclear medicine. In addition to publishing journals, newsletters, and books, the SNMMI also sponsors international meetings and workshops designed to increase the competencies of nuclear medicine practitioners and to promote new advances in the science of nuclear medicine. The European Association of Nuclear Medicine (EANM) is a professional nonprofit medical association that facilitates communication worldwide between individuals pursuing clinical and research excellence in nuclear medicine. The EANM was founded in 1985.

The SNMMI/EANM will periodically define new guidelines for nuclear medicine practice to help advance the science of nuclear medicine and to improve the quality of service to patients. Existing practice guidelines will be reviewed for revision or renewal as appropriate, on their fifth anniversary or sooner, if indicated.

Each practice guideline, representing a policy statement by the SNMMI/EANM, has undergone a thorough consensus process in which it has been subjected to extensive review. The SNMMI/EANM recognizes that the safe and effective use of diagnostic nuclear medicine imaging requires specific training, skills, and techniques, as described in each document.

The EANM and SNMMI have written and approved these guidelines to promote the use of nuclear medicine procedures with high quality. These guidelines are intended to assist practitioners in providing appropriate nuclear medicine care for patients. They are not inflexible rules or requirements of practice and are not intended, nor should they be used, to establish a legal standard of care. For these reasons and those set forth below, the SNMMI/EANM cautions

against the use of these guidelines in litigation in which the clinical decisions of a practitioner are called into question.

The ultimate judgment regarding the propriety of any specific procedure or course of action must be made by medical professionals taking into account the unique circumstances of each case. Thus, there is no implication that an approach differing from the guidelines, standing alone, is below the standard of care. To the contrary, a conscientious practitioner may responsibly adopt a course of action different from that set forth in the guidelines when, in the reasonable judgment of the practitioner, such course of action is indicated by the condition of the patient, limitations of available resources, or advances in knowledge or technology subsequent to publication of the guidelines.

The practice of medicine involves not only the science but also the art of dealing with the prevention, diagnosis, alleviation, and treatment of disease. The variety and complexity of human conditions make it impossible to always reach the most appropriate diagnosis or to predict with certainty a particular response to treatment. Therefore, it should be recognized that adherence to these guidelines will not ensure an accurate diagnosis or a successful outcome. All that should be expected is that the practitioner will follow a reasonable course of action based on current knowledge, available resources, and the needs of the patient to deliver effective and safe medical care. The sole purpose of these guidelines is to assist practitioners in achieving this objective.

I. INTRODUCTION

During the clinical evaluation of gastrointestinal symptoms suspected to be caused by a motility disorder, it may be difficult for clinicians to determine whether the symptoms are caused by upper or lower gastrointestinal tract dysfunction. In clinical practice, it is therefore helpful to evaluate motility throughout the entire gastrointestinal tract. At present, whole-gut transit scintigraphy (combined gastric emptying, small-bowel transit, and colon transit) is a relatively easy study to perform and in some centers is a frequently used and validated method to assess motility throughout the gut. Treatment selection may be guided by the finding of upper, lower, or combined gastrointestinal transit abnormalities. In addition, in patients with chronic constipation who are being considered for surgical colectomy, an assessment of upper gastrointestinal motility is important since upper gastrointestinal dysmotility may reduce the clinical response to surgical treatment.

Small- and large-bowel motility is the result of complex gastrointestinal contractions that promote the aboral movement of intestinal chyme and indigestible solids. The most physiologic measurement of gastrointestinal tract transit has been shown to be through imaging

Received Jul. 29, 2013; accepted Jul. 29, 2013.

For correspondence or reprints contact: Alan Maurer, Temple University Hospital/School of Medicine, 3401 N. Broad St., Broad and Ontario Streets, Philadelphia, PA 19140.

E-mail: amaurer@temple.edu

Published online Oct. 3, 2013.

*NOTE: YOU CAN ACCESS THIS GUIDELINE THROUGH THE SNMMI WEB SITE (<http://www.snmni.org/guidelines>).

COPYRIGHT © 2013 by the Society of Nuclear Medicine and Molecular Imaging, Inc.

DOI: 10.2967/jnumed.113.129973

normal foods labeled with a small amount of radiotracer. With minor modifications, small-bowel and colon transit scintigraphy studies are easily performed as a continuation of the standard gastric-emptying study. Other methods for measuring bowel transit include substrate-hydrogen breath tests for small-bowel transit, radioopaque markers for colon transit, and a wireless motility capsule for assessment of gastric, small-bowel, and large-bowel transit. However, indigestible solid particles such as the radioopaque markers (~4 mm in diameter) and wireless motility capsule (~10 mm in its longest axis) may not move through the gastrointestinal tract in the same manner as a physiologic meal (1,2).

A recent task force committee on gastrointestinal transit studies has stated that “the scintigraphic method is the only one that reliably allows the determination of both total and regional transit times” for gastrointestinal and colon transit (3). A position paper from the American Neurogastroenterology and Gastrointestinal Motility Society and the European Society of Neurogastroenterology and Motility states that scintigraphy is recommended for “detection of altered small-intestine transit in subjects with suspected diffuse gastrointestinal motility disorder” and that colon transit scintigraphy “offers reproducible and accurate performance,” as it measures whole-gut and regional colon transit in patients with suspected colonic motility disorders or more diffuse disorders involving the stomach or small intestine (4). The clinical value of performing small-bowel and colon transit studies using a dual-isotope solid-liquid gastric-emptying meal has been confirmed by demonstrating that these studies can alter the clinical diagnosis and management of patients with constipation in approximately 50% of cases (5,6).

Although scintigraphic methods for measuring small-bowel and colon transit have been in use for at least 20 y, they have not gained widespread use because of the lack of standardized methods for the studies and, in the United States, the lack of specified Current Procedural Terminology codes required for reimbursement. In the United States, there is an approved nuclear medicine Current Procedural Terminology code only for gastric emptying, and these studies thus are currently done with additional imaging and analysis after a standard solid or liquid gastric-emptying study without additional reimbursement (7–11).

II. GOALS

The purpose of this guideline is to assist nuclear medicine imaging practitioners in recommending, performing, interpreting, and reporting the results of transit studies of the small bowel and colon.

III. DEFINITIONS

Dual-isotope imaging: Acquisition of simultaneous images, typically using the separate imaging peaks of ^{99m}Tc and ^{111}In .

Whole-gut transit study: Measurement of gut motility from the stomach through the large bowel. This study is usually performed using a dual-isotope solid-phase (^{99m}Tc) and liquid-phase (^{111}In) gastric-emptying study followed by small-bowel and colon follow-through using the ^{111}In energy peak.

Small-bowel transit study: The performance either of a single-isotope liquid gastric-emptying study alone followed by additional imaging to record small-bowel transit or a dual-isotope study (combined solid-liquid gastric-emptying studies) followed by additional imaging to record small-bowel transit of the liquid meal. In either case, a liquid-phase meal is used, because liquid gastric

emptying is only rarely so delayed as to affect measurement of small-bowel transit.

Colon transit study: Use of orally ingested liquid (usually ^{111}In -diethylenetriamine pentaacetic acid [^{111}In -DTPA]) to monitor colon transit (5). Some institutions use specially prepared ^{111}In capsules that dissolve at more alkaline pH and release ^{111}In tracer activity in the terminal ileum (12).

Terminal ileum reservoir filling: Measurement of radiotracer activity that accumulates in the terminal ileum reservoir, as an index of small-bowel transit. The terminal ileum reservoir is that area in the distal small bowel where intestinal chyme accumulates before a bolus transfers into the colon. This method shortens the time needed for imaging small-bowel transit compared with methods that require imaging of the accumulation of colon activity.

Small-bowel transit time: An alternative approach to measuring small-bowel transit that quantifies the accumulation of radiotracer in the colon to calculate either small-bowel transit time 10% (defined as the time elapsed between 10% gastric emptying and 10% colon filling [a surrogate for small-bowel transit time 10% is the proportion arriving in the colon at 6 h]) or small-bowel transit time 50% (defined as the time elapsed between 50% gastric emptying and 50% colon filling).

Colon geometric center: A weighted average of the radioactivity counted in specific segments of the bowel, that is, the ascending, transverse, descending, and rectosigmoid colon and in the stool (regions 1–5) (12,13). Some authors further divide the large bowel to distinguish activity in hepatic and splenic flexures (regions 1–7) (5,14). The geometric center is then calculated as the sum of the weighted fraction of counts in each region, where the fractions in each region are based on the decay-corrected total counts available to fill the colon. It is similar to a center of mass of the distributed activity in the colon, providing a quantitative measure of the progression of radiolabeled stool as it moves through the colon.

IV. COMMON CLINICAL INDICATIONS

Indications for small-bowel and colon transit scintigraphy include, but are not limited to, evaluation of gastrointestinal and colon transit abnormalities as a cause of symptoms in patients with known or suspected gastroparesis, dyspepsia, irritable bowel syndrome, chronic constipation, chronic diarrhea, chronic idiopathic intestinal pseudoobstruction, scleroderma, celiac disease, and malabsorption syndromes. In the evaluation of patients with constipation, transit measurements may demonstrate a motility disorder or slow colon transit or may provide evidence to support a diagnosis of defecation disorder or functional rectosigmoid obstruction (3).

V. QUALIFICATIONS AND RESPONSIBILITY OF PERSONNEL

See the SNM Guideline for General Imaging.

VI. PROCEDURE/SPECIFICATIONS OF THE EXAMINATION

A. Study requisition

The requisition for the bowel motility study should include sufficient information to justify performance of the procedure and to direct the attention of the physician reading the study to the site of any suspected abnormality. Common indications are described above. This information may include symptoms or the presence of other systemic illness such as diabetes, celiac sprue, or scleroderma. Pertinent additional test results should also be reviewed when

available, such as other radiographic studies and results from endoscopy. It is particularly important to ensure that there is no obstruction or partial obstruction in a patient with delayed gastrointestinal transit. Relevant history, such as prior surgical procedures and current medications, should also be available for review, as well as a detailed gastrointestinal history including frequency of bowel movements and any routine use of laxatives.

B. Patient preparation and precautions

The preparation for small-bowel and colon transit studies is similar to that for a standard gastric-emptying study, which is usually acquired simultaneously (15). Before the study begins, patients should be questioned about food allergies, especially to eggs or gluten, and about other dietary restrictions. Patients are required to fast overnight or minimally for 8 h before the beginning of the procedure. They should discontinue medications that affect motility at least 48–72 h before the start of the procedure unless motility while on those medications is being investigated. Medications that should be stopped include opiate analgesics and anticholinergic medications, which slow gastrointestinal transit, and prokinetic agents (metoclopramide, domperidone, erythromycin), which accelerate gastrointestinal transit.

Diabetic patients should be instructed to bring their insulin and glucometer, if used, with them. They should administer their scheduled dose of insulin just before ingesting the test meal unless the supervising physician feels some modification in insulin dose is needed. Measurement of blood glucose in diabetics before and during the test may be helpful. Bowel motility studies should not be performed if the blood glucose level is high, for example, more than 250 mg/dL, at the time of the study since hyperglycemia can delay gastric emptying and affect small-bowel transit measurements (16).

For colon transit studies, medications that can affect gastrointestinal transit are typically withheld before and during the entire test. Patients are instructed not to take laxatives and are told to consume their typical diet for 2 d before the test and for the 4 d of sequential colon imaging. No other diagnostic studies should be scheduled during the 4 d after the start of imaging when small-bowel and colon transit imaging is being performed. This rule applies particularly to studies that would require alteration in normal eating patterns or ingestion of other agents, such as bowel radiologic contrast material.

C. Radiopharmaceuticals

Three radionuclide methods have been proposed for measuring small-bowel and colon transit:

1. Use of a standard mixed solid–liquid gastric-emptying meal, which has shown reproducible results in measurement of both solid and liquid small-bowel transit and also allows evaluation of colon transit (7,8). This method involves radiolabeling the liquid phase of a gastric-emptying meal, typically with ^{111}In -DTPA. As the liquid mixes with the intestinal chyme, transit of the radiolabel is used to assess small-bowel and colon transit.

2. Use of a specially prepared, delayed-release, methacrylate resin-coated capsule containing ^{111}In -labeled activated charcoal particles for measuring colon transit. The coated capsule dissolves on reaching the alkaline terminal ileum, releasing the radioisotope into the lumen (9).

3. Use of ^{67}Ga -complexes (10,11). This method is mentioned for completeness but is not included in this guideline as it has had only limited use and is not as well standardized as methods 1 and 2.

The 2 radioisotopes most commonly used for bowel motility studies are $^{99\text{m}}\text{Tc}$ and ^{111}In . When $^{99\text{m}}\text{Tc}$ is attached to sulfur colloid and bound to egg or given as $^{99\text{m}}\text{Tc}$ -DTPA, it will be nonabsorbable in the bowel. ^{111}In -DTPA is also nonabsorbable in the bowel.

The suggested activity range for ^{111}In -DTPA is 3.7 MBq (0.1 mCi) to 37 MBq (1.0 mCi) (Table 1). This dose is usually administered only for colon transit studies requiring more than 1 d of imaging. The suggested activity range for $^{99\text{m}}\text{Tc}$ -sulfur colloid is 18.5 MBq (0.5 mCi) to 37 MBq (1.0 mCi). Some investigators suggest use of a higher administered activity of $^{99\text{m}}\text{Tc}$ for dual-isotope studies to minimize the spillover (down-scatter) contribution from ^{111}In in the $^{99\text{m}}\text{Tc}$ energy window. $^{99\text{m}}\text{Tc}/^{111}\text{In}$ activity ratios ranging from 5:1 to 10:1 have been suggested (17).

^{111}In -chloride can also be used with the manufacture of coated capsules. The advantage of this method is that the orally ingested specialized capsules do not release the ^{111}In into the bowel until they are dissolved in the pH environment of the terminal ileum. The disadvantage is that these capsules are available only at imaging facilities capable of fabricating them.

D. Protocol options

For imaging gastrointestinal transit, 3 protocol options with various single or combination meals are available. These are summarized in Figure 1. The imaging parameters for the 3 protocol options are summarized in Figure 2.

For each option, images may be acquired with the patient either standing upright in front of a large-field-of-view γ -camera or supine. Once positioning has been established, the same positioning should be used for all images. The field of view should be able to include the total abdomen from the gastric fundus down to the pelvis. Paired

TABLE 1
Radiation Dose Estimates for Dual-Isotope Studies with $^{99\text{m}}\text{Tc}$ -Labeled Egg and ^{111}In -DTPA in Water (Adults) (23,28–30)

Radiopharmaceutical	Administered activity	Organ receiving largest radiation dose	Effective dose
$^{99\text{m}}\text{Tc}$ -labeled nonabsorbable markers (solids)	18.5–37 MBq/kg (0.5–1.0 mCi/kg)	Upper large intestine: 0.12 mGy/MBq (0.44 rad/mCi)	0.024 mSv/MBq (0.089 rem/mCi)
^{111}In -labeled liquids (DTPA)	3.7–37 MBq/kg (0.1–1.0 mCi/kg)	Lower large intestine: 1.9 mGy/MBq (7.1 rad/mCi)	0.34 mSv/MBq (1.3 rem/mCi)

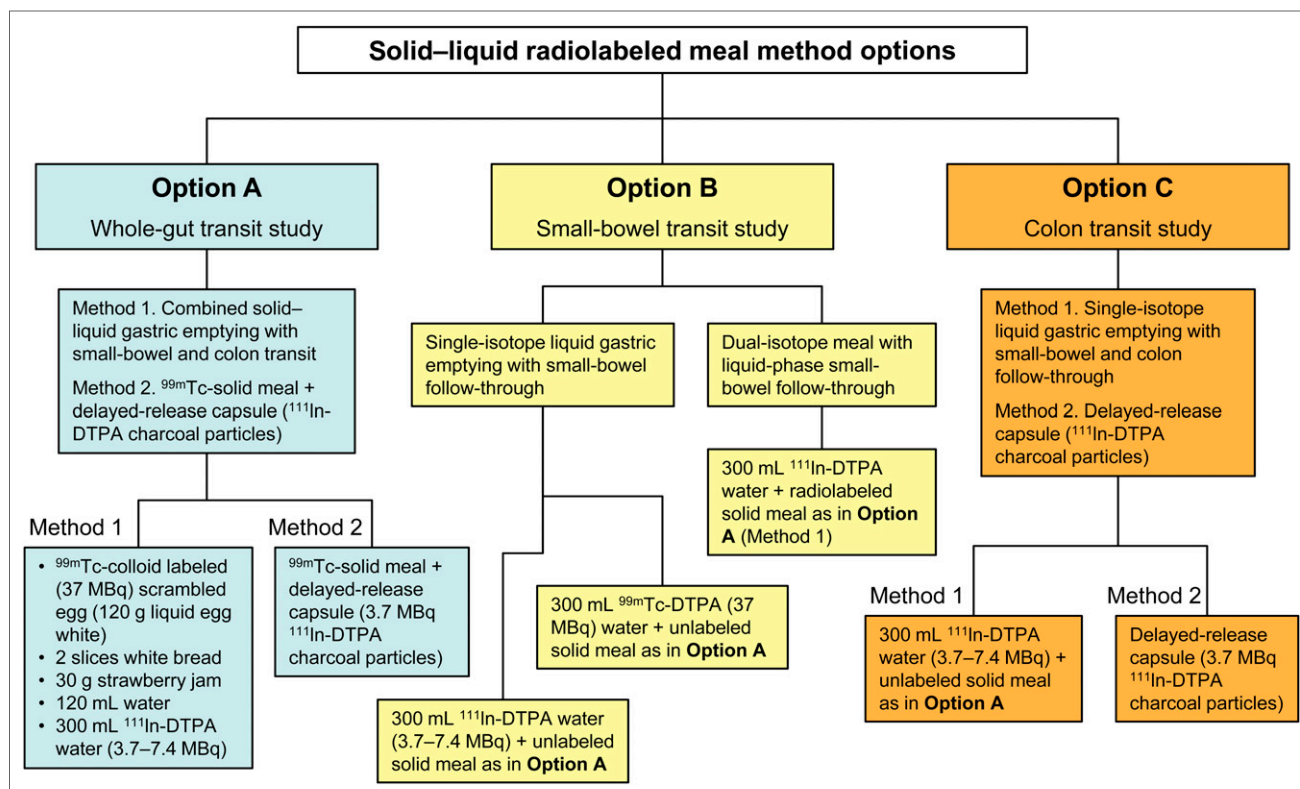


FIGURE 1. Gastrointestinal transit imaging options with various single or combination meals.

anterior and posterior images are acquired for all imaging times to calculate the geometric mean of region counts to compensate for photon attenuation, which may vary as activity transits throughout the abdomen.

E. Technical notes on the protocol options

1. Option A: Combined gastric-emptying, small-bowel, and colon transit study, or whole-gut transit (mixed solid-liquid dual-isotope radiolabeled meal).

When small-bowel and colon transit studies are performed as part of a combined solid-liquid gastric-emptying study, the solid-phase meal recommended is liquid egg white labeled with ^{99m}Tc as per the SNMMI Practice Guideline for Adult Solid-Meal Gastric-Emptying Study.

The complete dual-isotope, labeled test meal consists of a sandwich with ^{99m}Tc -sulfur colloid-labeled egg white (120 g [4 oz]; Egg Beaters [ConAgra Foods] or generic) and 300 mL of water containing 3.7–7.4 MBq (0.1–0.2 mCi) of ^{111}In -DTPA. The solid meal includes 18.5–37 MBq (0.5–1.0 mCi) of ^{99m}Tc -sulfur colloid-labeled egg white, 2 slices of white or wheat bread, 30 g of strawberry jam, and 120 mL of water. The isotope is added to the liquid egg mixture, which then is cooked in a microwave or on a skillet with intermittent stirring during cooking to promote mixing. The egg is served with the 2 slices of bread, the jam, and the water. The meal consists of 255 kcal, 24% protein, 2% fat, 72% carbohydrate, and 2% fiber.

Images are obtained in a 128×128 pixel matrix using a medium-energy collimator. The photopeak setting for ^{99m}Tc is 15% at 140 keV. For dual-isotope imaging, both the 172-keV and the 247-keV peaks for ^{111}In with 15%

windows can be used to maximize counts. If there is significant spillover from the ^{99m}Tc activity into the lower-energy 172-keV ^{111}In photopeak, a single 247-keV peak for ^{111}In can be used.

Each imaging site will need to individually evaluate potential spillover between the 2 energy windows. A cobalt position marker placed on the iliac crest helps to give an anatomic reference point.

As per the SNMMI Practice Guideline for Adult Solid-Meal Gastric-Emptying Study, initial solid-phase gastric-emptying images of 60 s each are acquired in anterior and posterior projections for 4 h to calculate geometric mean activity in the stomach and whole abdomen (15). Simultaneous anterior and posterior whole-abdomen images of the liquid phase using the ^{111}In -DTPA peaks are also acquired up to 4 h. After completion of the solid gastric-emptying images (4 h), additional anterior and posterior single-isotope ^{111}In -DTPA images at 5 and 6 h are acquired again for 60 s.

After the imaging for gastric-emptying and small-bowel transit, the patients resume their normal diet and activity. If medications are needed, the patients may take them with small sips of water during the 6 h required to complete the gastric-emptying and small-bowel studies. The patients return 24, 48, and 72 h after ingesting the meal for a single set of paired anterior and posterior whole-abdomen images of the ^{111}In -DTPA activity to assess colon transit. Images are obtained in a 128×128 pixel matrix, again using a medium-energy collimator for 4 min. Photopeak settings are unchanged. A cobalt position marker placed on the iliac crest again helps to give an anatomic reference point.

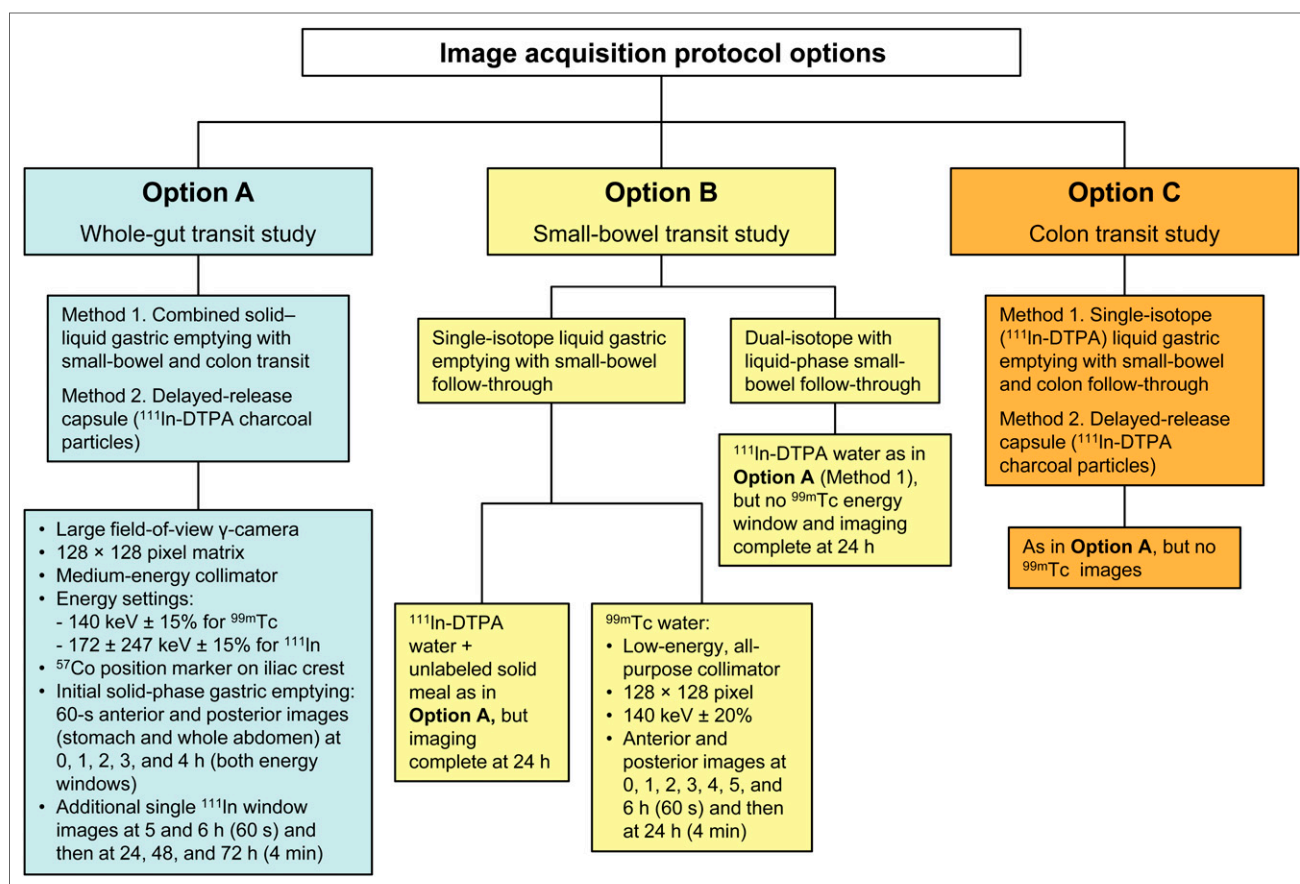


FIGURE 2. Imaging parameters for each gastrointestinal transit protocol option.

For final processing, all images are corrected for radioisotope decay and time per image. For example, counts for colon images (4 min per frame) at 24, 48, and 72 h need to be divided by 4 for comparison with 1-min images of total abdominal counts on the first day of the study.

2. Option B: Small-bowel transit study alone (single-isotope liquid gastric emptying performed with small-bowel imaging).

If only a small-bowel transit study is requested, it may be performed as a single-isotope study using ^{99m}Tc -DTPA (18.5–37 MBq [0.5–1.0 mCi]) in water accompanying an unlabeled standard solid gastric-emptying meal as described for option A. Use of ^{99m}Tc -DTPA is preferred over ^{111}In -DTPA as this will reduce the radiation dose to the patient and the half-life of ^{99m}Tc is sufficient to allow for measurement of small-bowel transit with appropriate decay correction. ^{99m}Tc -sulfur colloid mixed in water can also be considered for a single-isotope study. For single-isotope studies using only ^{99m}Tc , either a low-energy all-purpose or a low-energy high-resolution collimator may be used.

Although there are limited data on reference values for a liquid gastric-emptying study (water only, with no solid-phase meal), all small-bowel transit values discussed in the interpretation section of this guideline are based on oral administration of a mixed solid-liquid meal (17).

A large-field-of-view camera that includes the total abdomen from the gastric fundus down to the pelvis is again used. Images are obtained in a 128×128 matrix using

a low-energy all-purpose collimator for ^{99m}Tc . The photopeak setting is 20% at 140 keV for ^{99m}Tc . A cobalt position marker again may be placed on the iliac crest to give an anatomic reference point.

If terminal ileum filling at 6 h is used for interpretation, anterior and posterior images acquired at 0, 1, 2, 3, 4, 5, 6, and 24 h are obtained. The images at 24 h are used to localize activity in the cecum and ascending colon to aid in localizing the terminal ileum. The time for acquisition is increased to 4 min at 24 h to ensure adequate counts from the terminal ileum and cecum or any additional visualized colon. If a deconvolution method based on colon filling is used for interpretation, imaging may need to be continued beyond 6 h to visualize filling of the colon, which can be time-consuming.

3. Option C: Colon transit study only.

If only a colon transit study is requested, it can be performed using either of 2 methods. Method 1 is a single-isotope liquid gastric-emptying study with small-bowel and colon imaging. Since images are acquired up to 72 h after meal ingestion, the same protocol as detailed in option A (whole-gut transit study) is used but without radiolabeling the initial solid meal with ^{99m}Tc . Single-isotope imaging of the ^{111}In -DTPA in water is performed over 6 h on the first day and at 24, 48, and 72 h. Imaging at 2, 3, 4, and 5 h on the first day is required to obtain the average of the geometric mean-corrected anterior and posterior total abdominal images used as the input of total counts available to fill




FIGURE 3. Total abdominal and terminal ileum ROIs.

the colon needed to calculate the colon geometric center (Fig. 3). Analysis and interpretation are the same as for the combined study, but gastric-emptying and small-bowel analysis need not be performed.

Method 2 is a colon transit study using the coated-capsule method. This method requires preparation of a capsule coated with a pH-sensitive polymer, methacrylate, which is designed to dissolve and release its contents in the terminal ileum. This method is therefore limited to sites that can prepare such a capsule. Preparation requires mixing a slurry of 5 mg of activated charcoal with $^{111}\text{InCl}_3$. The mixture is dried at 90°C , and the dried charcoal is placed into a size 1 gelatin capsule and coated with pH-sensitive methacrylate (9,18). This measurement of colon transit may be used together with the standard $^{99\text{m}}\text{Tc}$ -sulfur colloid-labeled egg meal for simultaneous measurement of gastric emptying and small-bowel transit of a solid meal as described for option A.

For a whole-gut transit study using a dual-isotope $^{99\text{m}}\text{Tc}$ -sulfur colloid-labeled solid meal with the pH-sensitive methacrylate-coated capsule containing 3.7 MBq (0.1 mCi) of ^{111}In -labeled activated charcoal particles, the procedure is conducted as detailed for option A (whole-gut transit study). Images are obtained in a 128×128 pixel matrix using a medium-energy collimator for 4 min (2 min anterior and 2 min posterior). Photopeak settings are unchanged. A position marker placed on the iliac crest provides an anatomic reference point.

In contrast to the method using a dual-isotope mixed radiolabeled meal, where no additional meal is given, a lunch meal (550 kcal, chicken sandwich with potato and pudding) is consumed at 4 h after the start of the study (19).

F. Interpretation

Interpretation of small-bowel and colon transit studies requires both analysis of quantitative parameters and visual inspection of the images. The regions of interest (ROIs) should be checked for correct positioning, and visual analysis of tracer progression through the bowel should be confirmed by quantitative analysis.

G. Quantitative Analysis

1. Total abdominal counts analysis.

The ^{111}In -DTPA liquid-phase meal is generally used for small-bowel analysis because emptying of liquids from the stomach is more rapid than emptying of solids and only rarely is so delayed as to affect small-bowel transit analysis. A manually drawn large ROI to include the entire abdomen is used to obtain average total abdominal counts between 2 and 5 h, when all liquid has left the stomach and is distributed in the abdomen (Fig. 3). This average of the total abdominal counts is used to determine the counts available to fill the terminal ileum at 6 h (for small-bowel transit) and to enter the colon (for geometric center analysis). This average is obtained from the decay-corrected geometric mean total abdominal counts at

2, 3, 4, and 5 h after meal ingestion (Fig. 4).

For dual-isotope studies each imaging lab should determine the percentage of ^{111}In counts contributing to the $^{99\text{m}}\text{Tc}$ counts in the 140-keV window or $^{99\text{m}}\text{Tc}$ counts contributing to the ^{111}In window and perform any needed corrections for simultaneously acquired energy windows.

As shown in Figure 3, a large, rectangular ROI is used to determine total abdominal ^{111}In counts. At 5 h (300 min) after meal ingestion, there is clear accumulation of ^{111}In activity in the terminal ileum reservoir. An ROI to determine the percentage filling of the terminal ileum at 6 h is manually drawn (dotted circle and arrow in the figure). Any activity that has passed through the terminal ileum and into

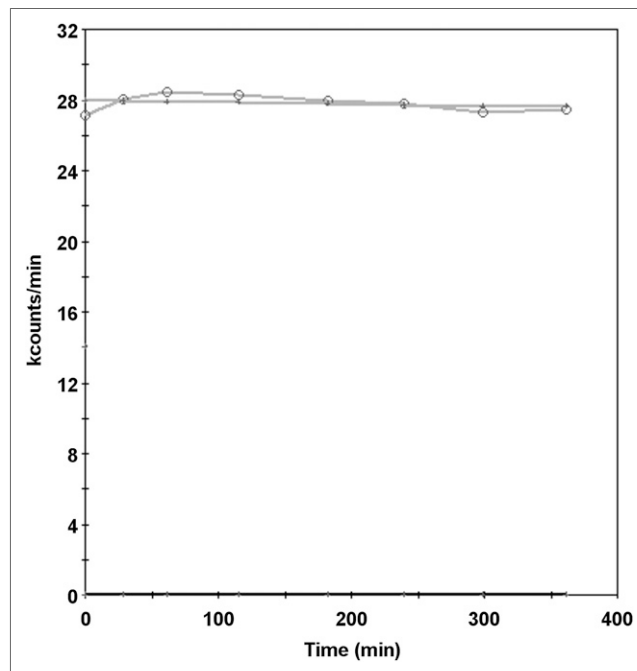


FIGURE 4. Total abdominal geometric mean counts.

the cecum or colon at 6 h should be included in the ROI as this activity has passed through the small bowel.

There is typically some variation in total abdominal counts over the course of the study, but usually the count variation is less than 10%. The average of the decay-corrected geometric mean ^{111}In counts between 2 and 6 h is used to quantify the total abdominal counts available to enter the terminal ileum and colon.

2. Small-bowel transit analysis.

It is well recognized that small-bowel motility is complex, with contraction patterns that differ between the proximal small bowel and distal small bowel. Although these patterns are complex, methods based on terminal ileum or colon filling have been proposed that provide simplified quantitative indices of overall small-bowel transit (12). To minimize the effect of variable output from the stomach, which can affect terminal ileum- and colon-filling methods, more complex methods that incorporate deconvoluting gastric emptying and colon filling have been described (1,20). These methods are less practical than simple measurement of terminal ileum or colon filling. Because of the need to measure colon filling, the latter requires significantly increased imaging time to ensure adequate colon filling.

3. Terminal ileum filling method.

Because of the stasis that occurs in the terminal ileum reservoir, a simple measurement of the total amount of ^{111}In activity accumulated in the terminal ileum or transited into the cecum and ascending colon at 6 h is used as an index of small-bowel transit. Studies have shown that the most rapid transit is in the proximal small bowel, with slowing occurring in the distal ileum. The terminal ileum serves as a reservoir and fills with activity before it crosses the ileocecal valve and enters the colon (21,22). Visually, the ^{111}In -labeled liquid meal activity is identified in the reservoir area and terminal ileum, and a manual ROI is drawn to encompass all activity in the terminal ileum (Fig. 3). If activity has progressed into the cecum or colon, that activity is considered to have transited through the small bowel and a larger ROI to include the terminal ileum and the cecum/colon is drawn to measure all the activity that has passed through the small bowel.

Imaging is continued up to 360 min on the first day to quantify the ^{111}In activity that transits into the terminal ileum reservoir or passes into the cecum or ascending colon. The patient returns 24 h after the beginning of the study (usually the next morning) for one anteroposterior image set of the abdomen to help with visual identification of the locations of the colon and terminal ileum. Anterior and posterior manual ROIs are drawn to include the ^{111}In activity in the terminal ileum or any activity that has passed into the colon at 6 h. The geometric mean decay-corrected percentage of activity that has passed into the terminal ileum reservoir (or into the colon) is calculated as follows:

$$\% \text{ activity transited through small bowel} = \frac{\text{total counts in terminal ileum} + \text{colon}^*}{\text{average total abdominal counts}^* (2\text{--}5 \text{ h after meal ingestion)}}$$

*Geometric mean and decay-corrected counts.

If more than 40% of the total abdominal ^{111}In counts administered has moved through the small bowel into the terminal ileum or colon, small-bowel transit is normal (5).

Visual interpretation should also accompany the quantitative analysis. Delayed small-bowel transit is typically seen as residual activity in multiple loops of small bowel without clear activity having progressed into the terminal ileum or colon. The 24-h image (second day) is used to visualize the colon in questionable cases for which the terminal ileum is not clearly identified in earlier images. In most cases of delayed small-bowel transit, activity is seen to persist in loops of small bowel, with no clear arrival in the terminal ileum or colon at 6 h. Rapid small-bowel transit can visually be detected by identifying early cecal filling ($\geq 10\%$ of administered activity in the cecum) in less than 70 min, with a reference range of between 72 and 392 min for cecal arrival in the dual-isotope meal method (23).

4. Colon-filling method.

The amount of colon filling at 6 h has also been used as an index of small-bowel transit. The range for normal filling of the colon at 6 h using nondigestible particles is 11%–70%. The range for digestible solids is 43%–95%, with rapid small-bowel transit defined as cecal arrival at less than 90 min (12).

5. Deconvolution method incorporating gastric emptying and colon filling.

Deconvolution was first proposed by Malagelada in 1984 (24) and was modified by Brinch et al. in 1999 (20). These methods result in an expected small-intestine time–activity curve if gastric emptying were instantaneous. The curve can be used to calculate a mean transit time for the bulk of radiolabeled material. This protocol, however, requires frequent (every 30 min) imaging and lengthy acquisitions until all tracer has passed into the colon. A simplification to this method was proposed by Read et al. in 1986 and is based on subtraction of 50% gastric-emptying time from the time to 50% colon filling (22).

H. Small-bowel transit time

Normal small-bowel transit time can vary depending on the methods used. Using resin pellets mixed with a meal, small-bowel transit time in healthy individuals reportedly ranged from 151 to 290 min (18). Using the liquid phase of a mixed solid–liquid meal, small-bowel transit time ranged from 72 to 392 min in healthy individuals (23). In some cases, there is prolonged stasis of activity in the terminal ileal reservoir, particularly if no second meal is administered. This may result in the need for imaging beyond 6 hours—which is also impractical—to see progression into the cecum or ascending colon.

I. Interpretation of colon transit scintigraphy

Various approaches to recording colon transit have been reported. Some advocate imaging at 24, 48, 72, and 96 h (6). Others suggest imaging only up to 48 h. Healthy individuals typically show complete colon evacuation by 72 h. Imaging up to 72 h is needed particularly to be able to diagnose functional rectosigmoid outlet obstruction and to localize any sites of functional obstruction in the colon (5).

Quantification of colon transit is based on serial measurement of the geometric center of a liquid meal as

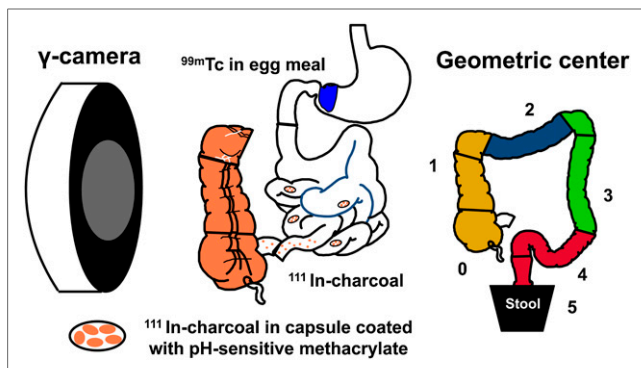


FIGURE 5. Method for analyzing 5 colonic ROIs using delayed-release radiolabeled charcoal particles. (Adapted with permission of (26).)

it moves through the colon. The geometric center is a weighted average of the radioactivity counted over specific segments of the colon, that is, the ascending, transverse, descending, and rectosigmoid colon. The geometric center is calculated as the sum of a weighted fraction represented by the counts in each region multiplied by the region number divided by the total counts.

Two methods have been most widely reported for quantifying geometric-center colon transit scintigraphy (5,25).

1. Charcoal in delayed-release capsule.

This first method designates numbers from 1 to 5 for counts in the colonic regions, as well as the activity in defecated stool, as weighting factors. This method is based on use of the special delayed-release capsule that delivers radiolabeled charcoal into the ileocolonic region (Fig. 5). With this method, reference values are a geometric center of less than 1.4 at 4 h, with a range of 1.6–3.8 at 24 h and 3.0–4.8 at 48 h (12,13). Slow colon transit is defined as a geometric center less than these reference values at 24 and 48 h. Table 2 provides the reference values published using this method (25).

2. Liquid-phase meal.

The second method is based on oral administration of an ^{111}In -DTPA–radiolabeled liquid meal and is usually

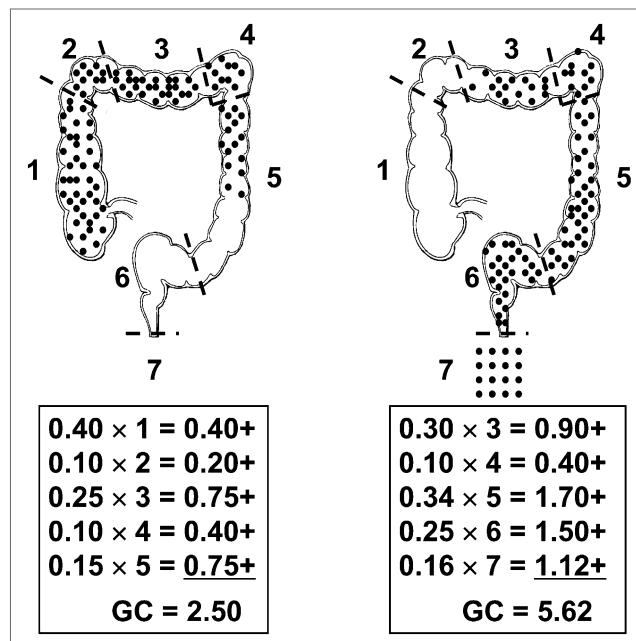


FIGURE 6. Method for analyzing 6 colonic ROIs.

performed as a part of a whole-gut transit study. This method designates numbers from 1 to 7 for counts in the ascending colon, hepatic flexure, transverse colon, splenic flexure, descending colon, rectosigmoid, and evacuated stools as the weighting factors (23) (Fig. 6). The reference values for the geometric center range are 2.0–7.0 for 24 h, 4.6–7.0 for 48 h, and 6.0–7.0 for 72 h.

Thus, a low geometric center implies that most of the radiolabeled material is close to the cecum (region 1), whereas a high geometric center indicates that most of the radiolabeled material is in the rectosigmoid or has passed through the colon into the excreted stool (regions 6 and 7). To determine the amount of activity that has been defecated and left the body (region 7), counting of activity in the stool is not required. Excreted-stool activity can be inferred from the total available counts on day 1 of the study obtained from the average of total abdominal counts between 2 and 5 h (as described for terminal ileum filling analysis of small-bowel transit). After decay correction, the counts remaining in the body are subtracted from the total initially available, and the difference is the activity that has been excreted.

With a liquid meal and the 7-ROI geometric center analysis, 3 abnormal patterns have been described: generalized slow colon transit, colonic inertia, and functional rectosigmoid obstruction (Fig. 7) (3). Although scintigraphy can demonstrate slow colon transit, a precise diagnosis of colonic inertia needs to be confirmed by the lack of manometric response of the colon to a meal and neostigmine. A pattern suggestive of functional outlet obstruction similarly needs further evaluation with contrast defecography and anal manometry.

A generalized slow pattern for colon transit is typically seen as delayed progression, a persistent diffuse retention of activity throughout all segments of the colon, and a geometric center of less than 4.1 at 48 h and between 4.1 and

TABLE 2

Reference Values for Colon transit Parameters Using Delayed-Release Capsule Method (25)

Parameter	Data
Total no. of healthy volunteers	211
Geometric center at 24 h (mean \pm SD)	2.4 ± 0.9 ($n = 209$)
10th–90th percentile	1.47–3.87
Men (mean \pm SD)	2.7 ± 0.9 ($n = 72$)
Women (mean \pm SD)	2.3 ± 0.9 ($n = 137$)
Geometric center at 48 h (mean \pm SD)	3.6 ± 1.1 ($n = 191$)
10th–90th percentile	2.13–5.00
Men (mean \pm SD)	4.1 ± 1.0 ($n = 61$)
Women (mean \pm SD)	3.4 ± 1.0 ($n = 130$)

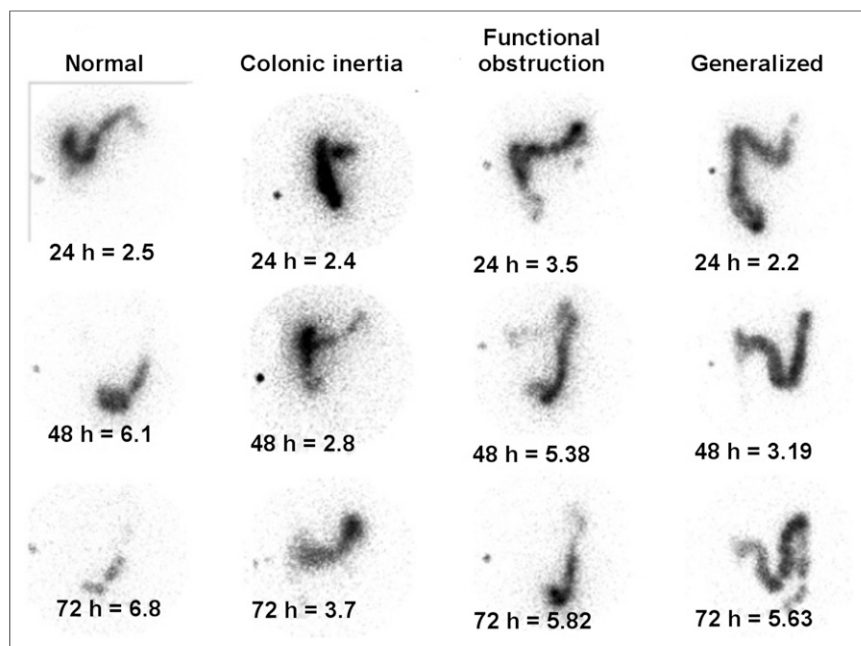


FIGURE 7. The 3 abnormal patterns: generalized slow colon transit, colonic inertia, and functional rectosigmoid obstruction. (Adapted with permission of (3).)

6.2 at 72 h. The pattern described as suggestive of colonic inertia demonstrates failure of the radiotracer to progress beyond the splenic flexure, with a geometric center of less than 4.1 at 48 and 72 h. Functional outlet obstruction is present when activity has progressed into the rectosigmoid colon but then fails to be expelled, with a geometric center of more than 4.1 at 48 h and less than 6.2 at 72 h. Figure 7 summarizes these patterns compared with a normal colon transit pattern (3).

J. Potential sources of error in small-bowel transit studies

The measurement of small-bowel transit using an orally administered agent is always complicated by its dependency on gastric emptying. An advantage of using a simple liquid (water) is that liquid gastric emptying is rarely so delayed as to significantly affect small-bowel transit. All interpretation of small-bowel transit, however, does require simultaneous assessment of liquid gastric emptying to ensure it has not been unusually delayed. Only in cases of severe liquid gastric retention (>50% retention at 2 h) does the report on small-bowel transit need to be qualified as nondiagnostic because of marked delayed gastric emptying of the liquid meal.

Filling of the terminal ileum using a mixed solid-liquid radiolabeled meal is reproducible in healthy subjects who demonstrate ileocecal transfer beginning within 6 h (7). There is, however, potential difficulty in distinguishing stasis in the terminal ileum from activity in the cecum at 6 h. The stasis that occurs in the terminal ileum reservoir before filling the colon has been reported in multiple small-bowel motility studies (8,22). Review of the 24-h image, which typically will demonstrate activity in the colon and complete clearance from the small bowel, is helpful for determining whether activity in the terminal

ileum was correctly localized. In some cases, definite localization of the terminal ileum may be difficult even with delayed imaging.

A potential error in assessment of small-bowel transit may occur in the presence of delayed colon transit. The small bowel may be unable to empty into the colon, providing a potential false-positive in the assessment of small-bowel transit. Therefore, the small-bowel transit can be deemed diagnostic only if gastric emptying of the radiolabeled liquid and colon transit are normal.

As with any gastrointestinal motility study, the reference values for small-bowel transit depend on strict adherence to the standardized meals described in this guideline. Any deviations from the recommended meal preparation, amounts ingested, and imaging times may lead to errors in interpretation.

K. Potential sources of error in colon transit studies

Medications can affect gastrointestinal transit results. Prokinetic agents such as metoclopramide, domperidone, erythromycin, and prucalopride can increase gastric emptying and gastrointestinal transit in general. These may normalize transit in a patient who might otherwise have slow transit. Narcotic analgesic agents and anticholinergic agents slow gastrointestinal transit. These may slow transit in a patient who might otherwise have normal transit.

Fecal impaction in the colon may further retard gastrointestinal transit through the colon. On occasion, it might be prudent to clean out the gastrointestinal tract with a cathartic before performing a colon transit assessment.

Partial obstruction from adhesions, anastomotic narrowing, or large intrinsic gastrointestinal lesions such as colon cancer may slow colon transit.

Although visual inspection is usually adequate for proper identification of the ROIs for calculation of the geometric center of colon activity, these segments may overlap significantly. Overlap usually occurs at the borders of the segments and in fact results in only small variations in the overall calculated geometric center. Colon transit measurement provides an overall summary of transit but is not definitively diagnostic of a specific underlying pathophysiology, such as evacuation disorder versus slow-transit constipation or colonic inertia. At least one study has demonstrated a reduction of propulsive capacity of the colon with normal aging (27). At present, there are no adjusted reference values for colon transit measurement that reflect the changes with aging.

Again, as with any gastrointestinal motility study, the reference values for colon transit are dependent on strict adherence to use of the standardized meals described in this guideline. Any deviations from the recommended meal preparation, amounts ingested, and imaging times may lead to errors in proper interpretation.

VII. DOCUMENTATION/REPORTING

For the goals of a nuclear medicine report and information on direct communication, see the SNMMI Guideline for General Imaging.

VIII. EQUIPMENT SPECIFICATIONS

See the SNMMI Guideline for General Imaging.

IX. QUALITY CONTROL AND IMPROVEMENT

See the SNMMI Guideline for General Imaging.

X. SAFETY, INFECTION CONTROL, AND PATIENT EDUCATION CONCERNS

See the SNMMI Guideline for General Imaging.

XI. RADIATION SAFETY IN IMAGING

See the SNMMI Guideline for General Imaging.

XII. ACKNOWLEDGMENTS

Dr. Italia Paglianiti (Regional Center of Nuclear Medicine, University Hospital of Pisa, Pisa, Italy) helped with defining the flowcharts to illustrate the technical and imaging options A, B, and C included in this guideline.

XIII. REFERENCES

1. Madsen JL, Larsen N, Hilsted J, Worning H. Scintigraphic determination of gastrointestinal transit times: a comparison with breath hydrogen and radiologic methods. *Scand J Gastroenterol*. 1991;26:1263–1271.
2. Southwell BR, Clarke M, Sutcliffe J, Hutson J. Colonic transit studies: normal values for adults and children with comparison of radiological and scintigraphic methods. *Pediatr Surg Int*. 2009;25:559–572.
3. Lin HC, Prather C, Fisher R, et al. Measurement of gastrointestinal transit: AMS task force committee on gastrointestinal transit. *Dig Dis Sci*. 2005;50:989–1004.
4. Rao SS, Camilleri M, Hasler W, et al. Evaluation of gastrointestinal transit in clinical practice: position paper of the American and European neurogastroenterology and motility societies. *Neurogastroenterol Motil*. 2011;23:8–23.
5. Bonapace ES, Maurer AH, Davidoff S, Krevsky B, Fisher RS, Parkman HP. Whole gut transit scintigraphy in the clinical evaluation of patients with upper and lower gastrointestinal symptoms. *Am J Gastroenterol*. 2000;95:2838–2847.
6. Mclean RG, King D, Talley N, Tait A, Freiman J. The utilization of colon transit scintigraphy in the diagnostic algorithm for patients with chronic constipation. *Dig Dis Sci*. 1999;44:41–47.
7. Bennink R, Peeters M, Van den Maegdenbergh V, et al. Evaluation of small-bowel transit for solid and liquid test meal in healthy men and women. *Eur J Nucl Med*. 1999;26:1560–1566.
8. Krevsky B, Maurer A, Niewiarowski T, Cohen S. Effect of verapamil on human intestinal transit. *Dig Dis Sci*. 1992;37:919–924.
9. Burton DD, Camilleri M, Mullan B, Forstrom L, Hung J. Colonic transit scintigraphy labeled activated charcoal compared with ion exchange pellets. *J Nucl Med*. 1997;38:1807–1810.
10. Bartholomeusz D, Chatterton B, Bellen J, Gaffney R, Hunter A. Segmental colonic transit after oral ^{67}Ga -citrate in healthy subjects and those with chronic idiopathic constipation. *J Nucl Med*. 1999;40:277–282.

11. Bellen JC, Chatterton B, Penglis S, Tsopeles C. Gallium-67 complexes as radioactive markers to assess gastric and colonic transit. *J Nucl Med*. 1995;36:513–517.
12. Szarka LA, Camilleri M. Methods for the assessment of small-bowel and colonic transit. *Semin Nucl Med*. 2012;42:113–123.
13. Proano M, Camilleri M, Phillips S, Brown M, Thomforde G. Transit of solids through the human colon: regional quantification in the unprepared bowel. *Am J Physiol*. 1990;258:G856–G862.
14. Mariani G, Pauwels EK, AlSharif A, et al. Radionuclide evaluation of the lower gastrointestinal tract. *J Nucl Med*. 2008;49:776–787.
15. Donohoe KJ, Maurer A, Ziessman H, Urbain J, Royal H, Martin-Comin J. Procedure guideline for adult solid-meal gastric-emptying study 3.0. *J Nucl Med Technol*. 2009;37:196–200.
16. Schwarcz E, Palmer M, Aman J, Horowitz M, Stridsberg M, Berne C. Physiological hyperglycemia slows gastric emptying in normal subjects and patients with insulin-dependent diabetes mellitus. *Gastroenterology*. 1997;113:60–66.
17. Ziessman HA, Chander A, Clarke J, Ramos A, Wahl R. The added diagnostic value of liquid gastric emptying compared with solid emptying alone. *J Nucl Med*. 2009;50:726–731.
18. Camilleri M, Zinsmeister A, Greydanus M, et al. Towards a less costly but accurate test of gastric emptying and small bowel transit. *Dig Dis Sci*. 1991;36:609–615.
19. Prather CM, Camilleri M, Zinsmeister A, McKinzie S, Thomforde G. Tegaserod accelerates orocecal transit in patients with constipation-predominant irritable bowel syndrome. *Gastroenterology*. 2000;118:463–468.
20. Brinch K, Larsson H, Madsen J. A deconvolution technique for processing small intestinal transit data. *Eur J Nucl Med*. 1999;26:272–276.
21. Connel A. Propulsion in the small intestine. *Rendic R Gastroenterol*. 1970;2:38–46.
22. Read NW, Al-Janabi M, Holgate A, Barber D, Edwards C. Simultaneous measurement of gastric-emptying, small bowel residence and colonic filling of a solid meal by the use of the gamma camera. *Gut*. 1986;27:300–308.
23. Maurer AH, Krevsky B. Whole-gut transit scintigraphy in the evaluation of small-bowel and colon transit disorders. *Semin Nucl Med*. 1995;25:326–338.
24. Malagelada J, Robertson J, Brown M, et al. Intestinal transit of solid and liquid components of a meal in health. *Gastroenterology*. 1984;87:1255–1264.
25. Nullens S, Nelson T, Camilleri M, et al. Regional colon transit in patients with dyssynergic defecation or slow transit in patients with constipation. *Gut*. 2012;61:1132–1139.
26. Vazquez-Roque MI, Camilleri M, Carlson P, et al. HLA-DQ genotype is associated with accelerated small bowel transit in patients with diarrhea-predominant irritable bowel syndrome. *Eur J Gastroenterol Hepatol*. 2011;23:481–487.
27. Madsen JL, Graff J. Effects of ageing on gastrointestinal motor function. *Age Ageing*. 2004;33:154–159.
28. International Commission on Radiological Protection. *ICRP Publication 80: Radiation Dose to Patients from Radiopharmaceuticals*. St. Louis, MO: Elsevier; 1999.
29. Siegel JA, Wu RK, Knight LC, et al: Radiation dose estimates for oral agents used in upper gastrointestinal disease. *J Nucl Med*. 1983;24:835–837.
30. Stabin MG, Sparks RB, Crowe E. OLINDA/EXM: the second-generation personal computer software for internal dose assessment in nuclear medicine. *J Nucl Med*. 2005;46:1023–1027.

XIV. APPROVAL

This practice guideline was approved by the Board of Directors of the SNMMI on September 29, 2013, and by the EANM Executive Committee on August 28, 2013.